Karolinska Institutet

KAROLINSKA Universitetssjukhuset

Extracorporeal Membrane Oxygenation for LTB in humans

Magnus Larsson MD, PhD, Consultant Paediatric Surgery

Paediatric Surgery /ECMO/Dept. of Molecular Medicine and Surgery, Karolinska University Hospital

First Traumapatient on By-pass

Dr. JD Hill San Fransisco 1972

- ✓ 24 year old male, MC-accident
- ✓ Aortic Rupture
- ✓ Surgery on By pass
- ✓ Post Traumatic ARDS
- ✓ Continued ECLS 75 hours
- ✓ Survived wo handicap

Hill. N Engl J Med 1972

ECMO: Extracorporeal Membrane Oxygenation

Benefits

- O_2↑
- CO_2↓
- Temperature↑
- Stabilizes circulation
- Lung rest
- Keeps the patient alive

Risks

- Cannulation injury
- Bleeding
- Thromboembolism
- Life threatening

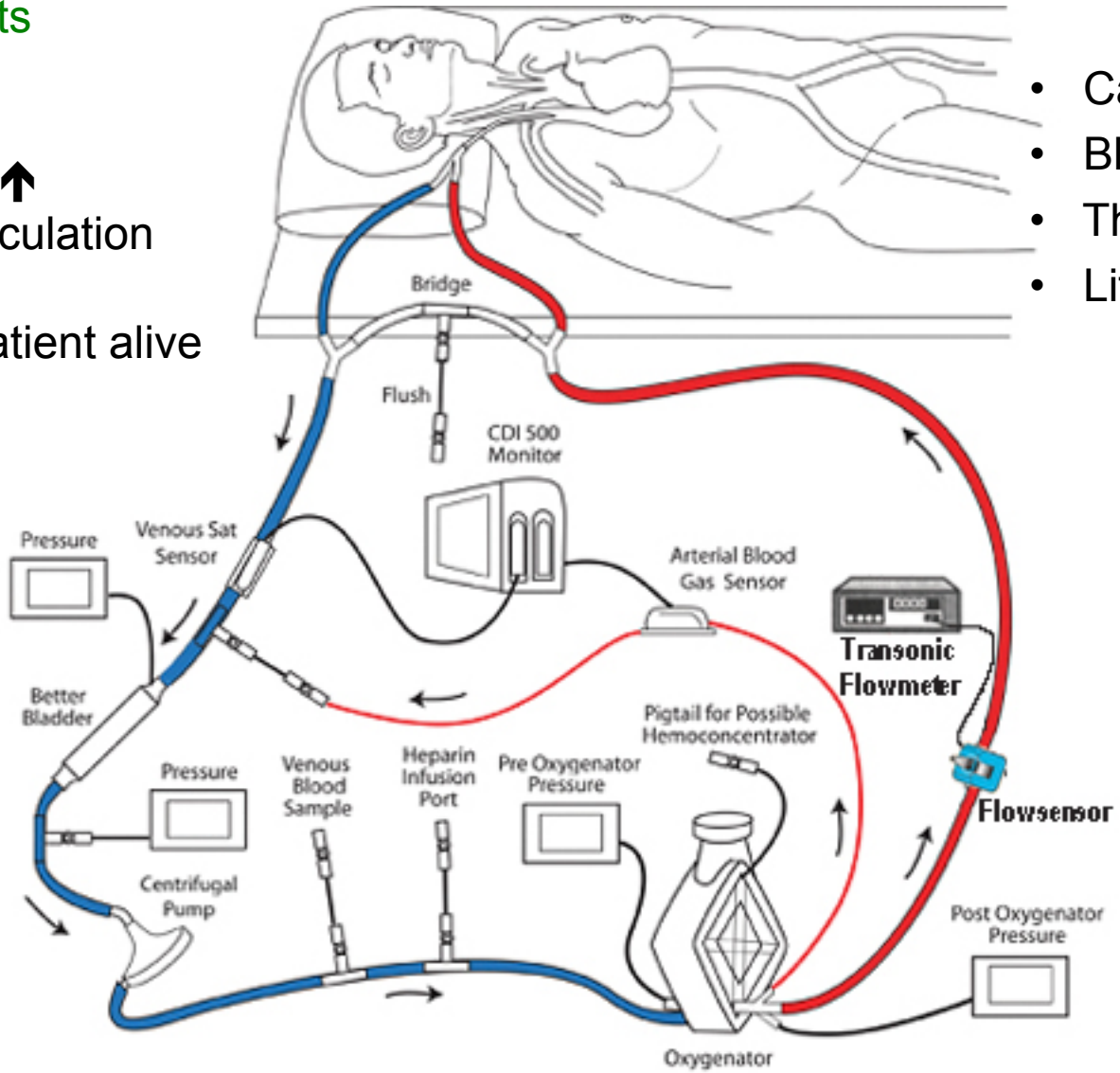

Trauma-ECMO

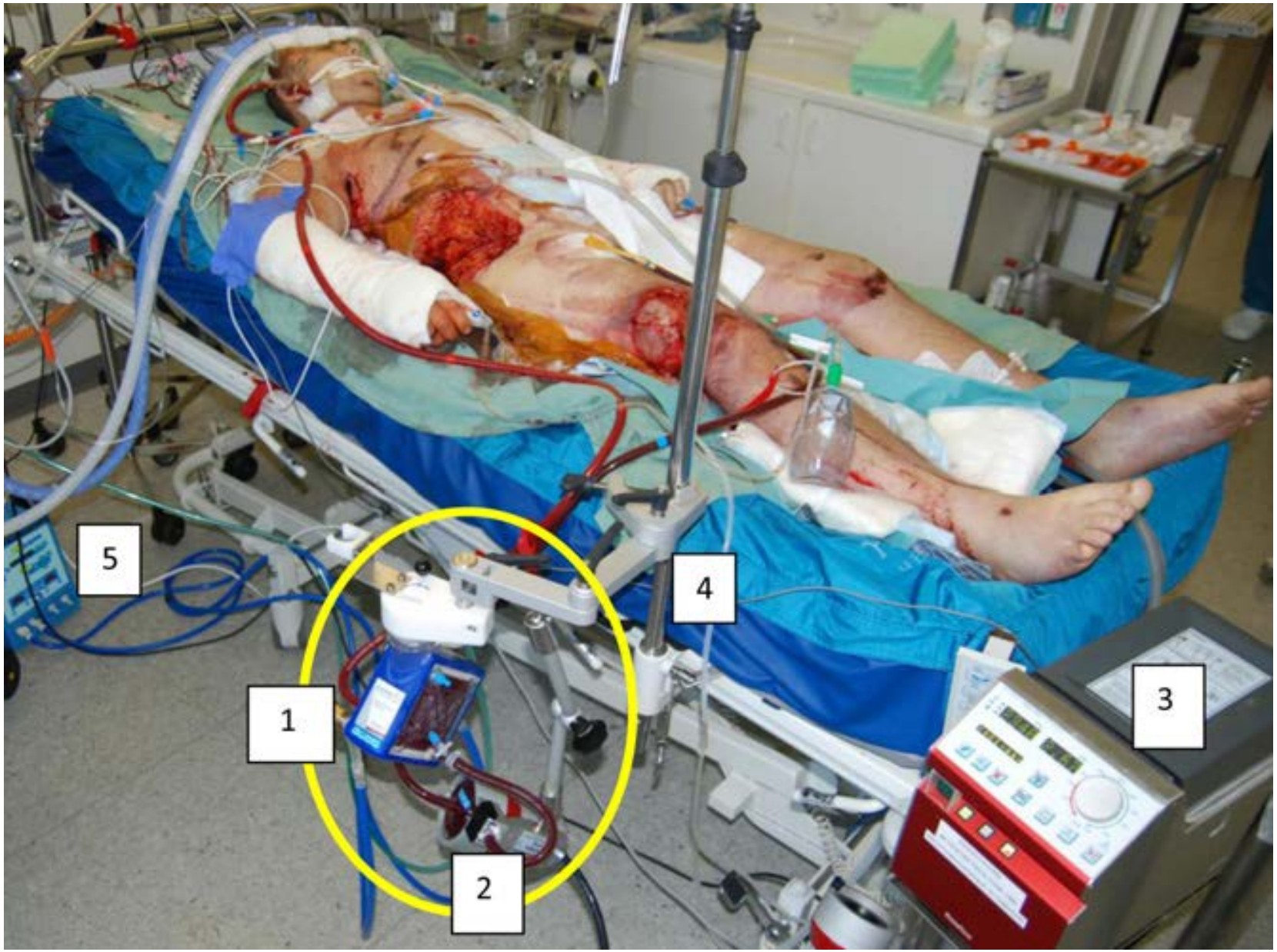

(1) Membraneoxygenator; (2) Centrifugalpump; (3) Rotaflow control and steeringunit; (5) Heatexchange unit

Cannulation in trauma

1. Ultrasound guided percutaneous route *or*
2. Cut down/ semipercutaneous route
3. Max10 min/site

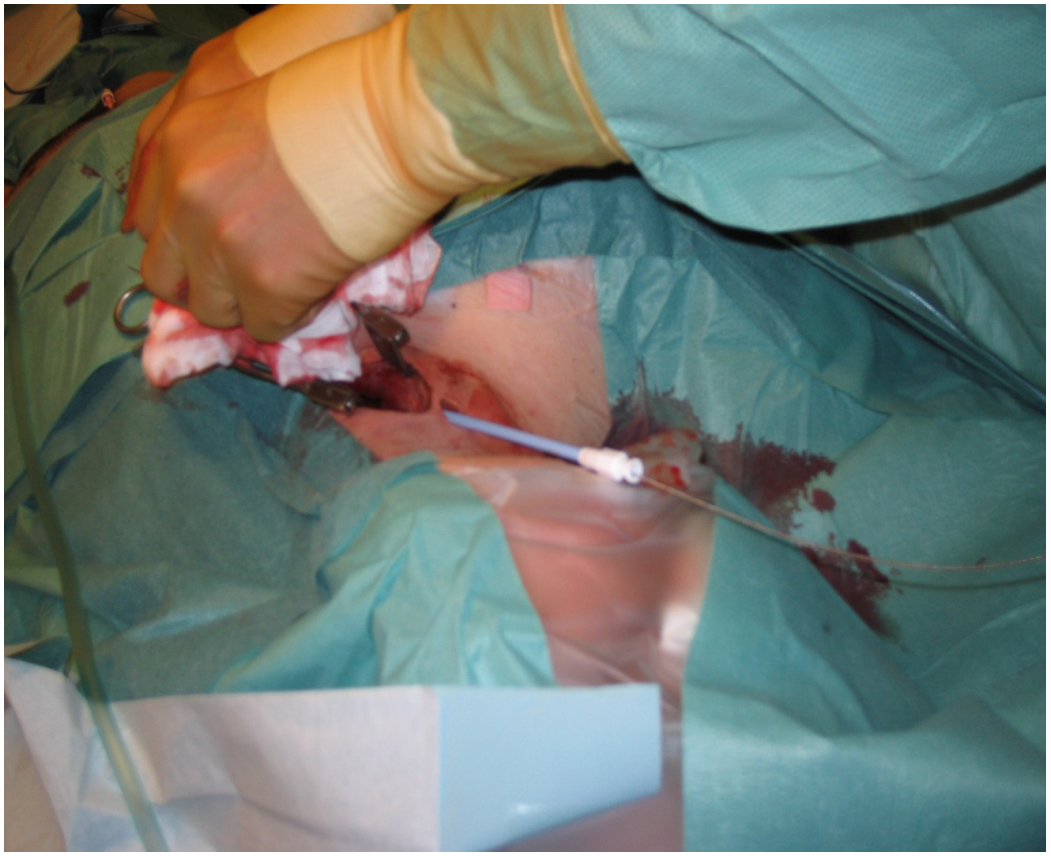

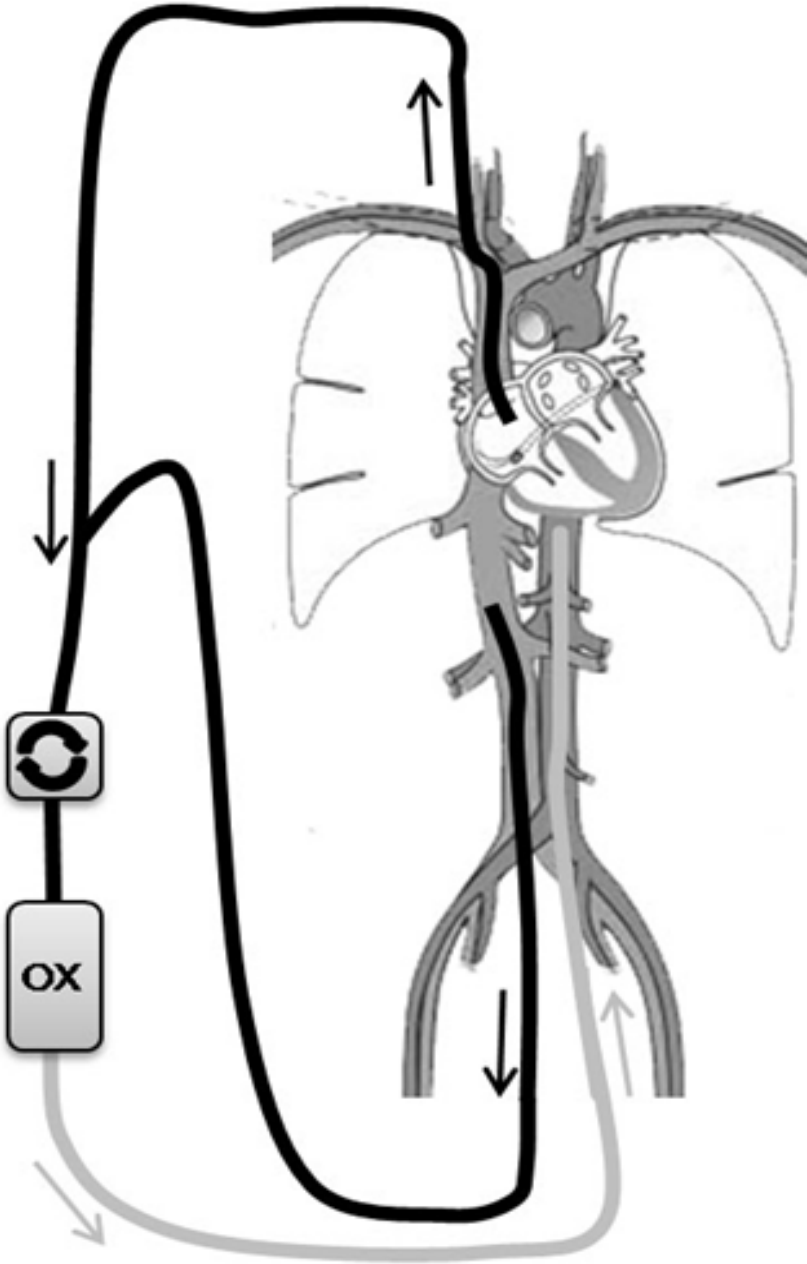

Cannulation in the groin

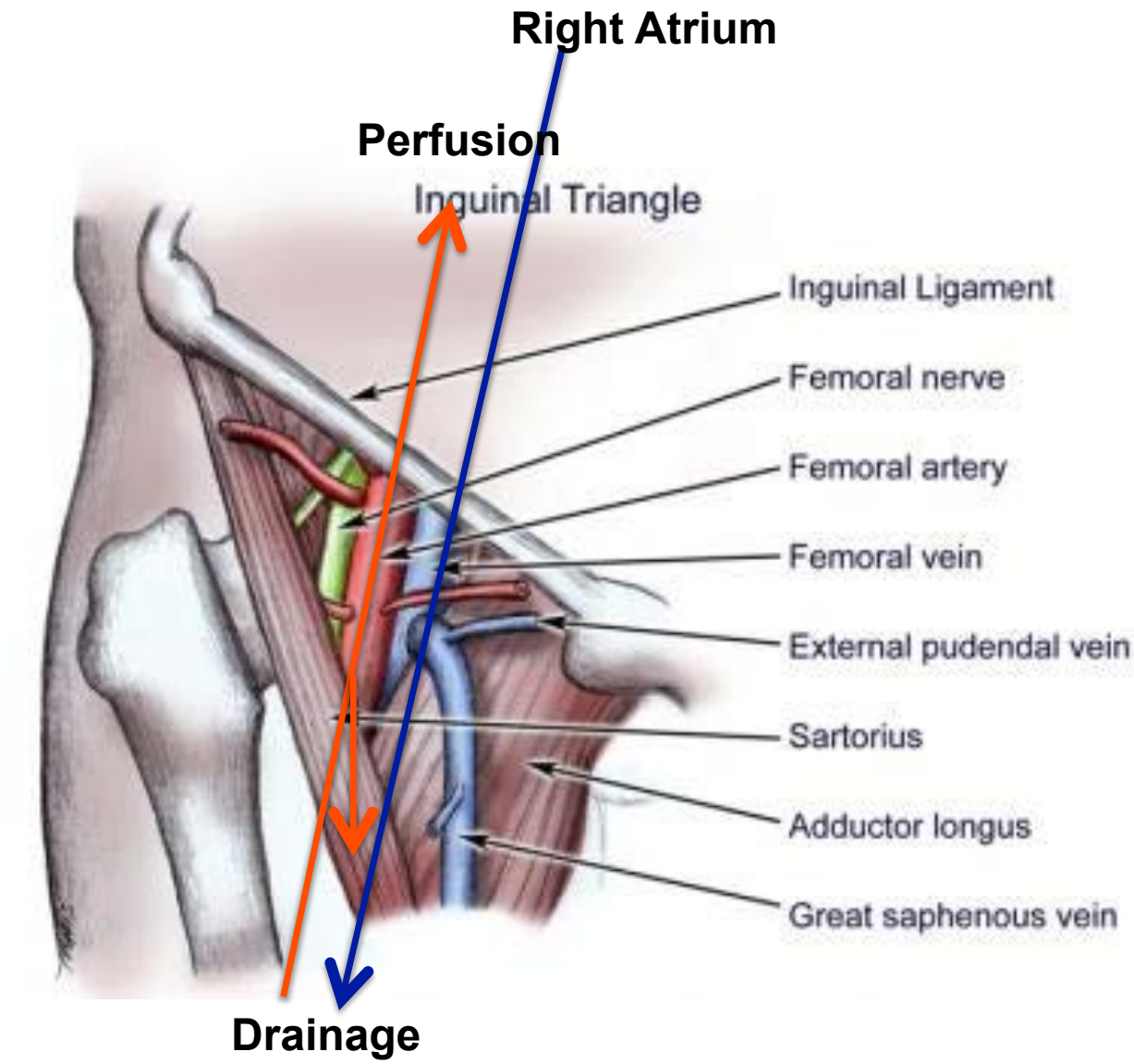

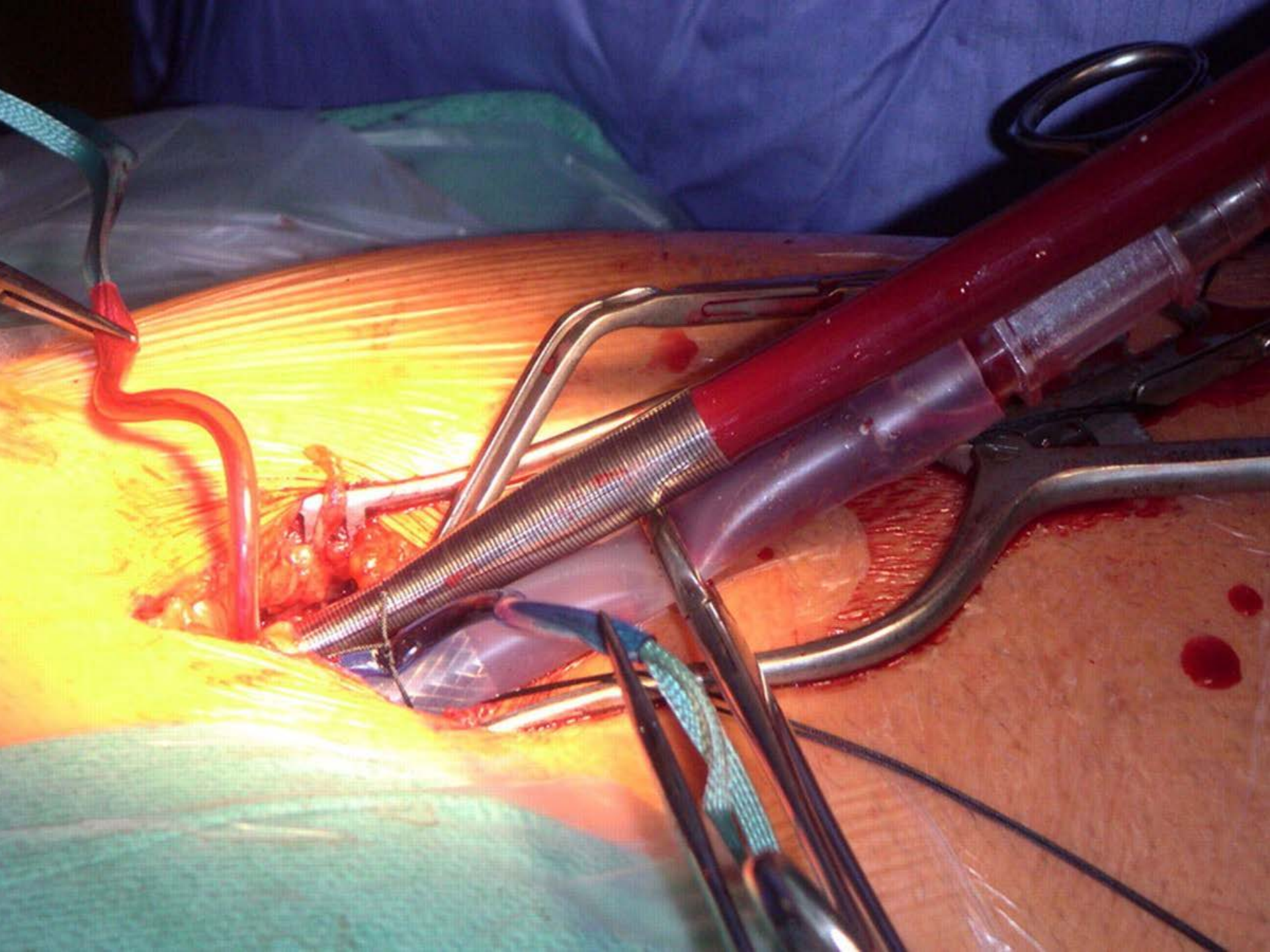

20 Years of ECMO-Trauma experience

- ✓ The Trauma and ECMO units are close at Karolinska
- ✓ Dedicated team 365-24-7. >1200 pat 850 Tp fixed wing
- ✓ 1997-2017: Trauma on ECMO n=50
- ✓ Male: 86% Female 14%
- ✓ VA: 48% VV: 52%
- ✓ By pass time: Mean = 113 h (1.00 h - 573.5 h)
- ✓ ARDS 78%: Post Trauma ARDS By-pass within 24 h VV-ECMO.
- ✓ ECPR 22%: Hypovolaemic Shock, Mean ISS 63
  Cardiac Arrest (73%)
  By-pass within 6 h VA ECMO.

Non-published data

Trauma mechanism

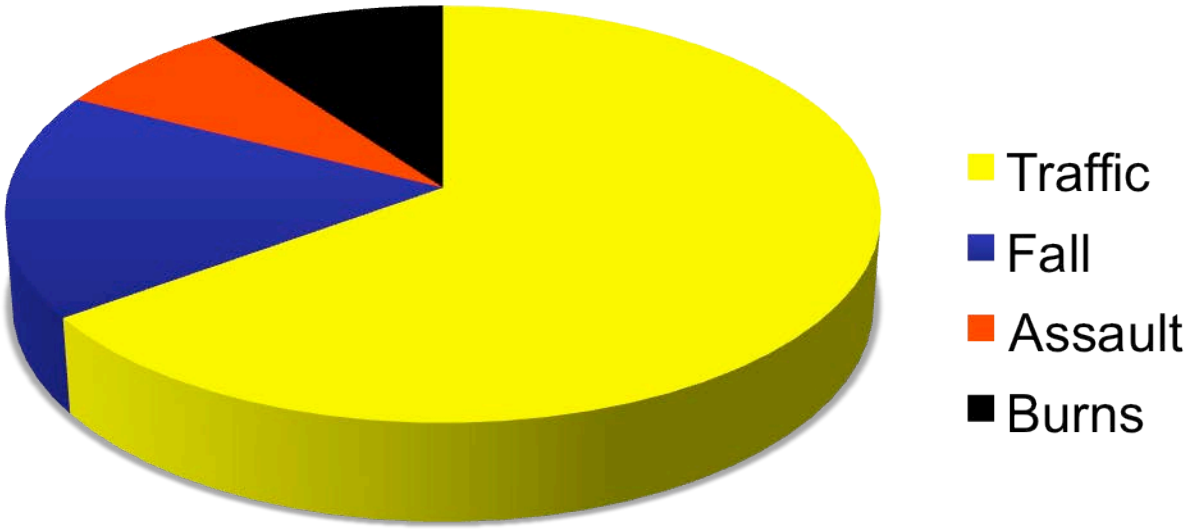

62.5% Traffic

ECMO Indication

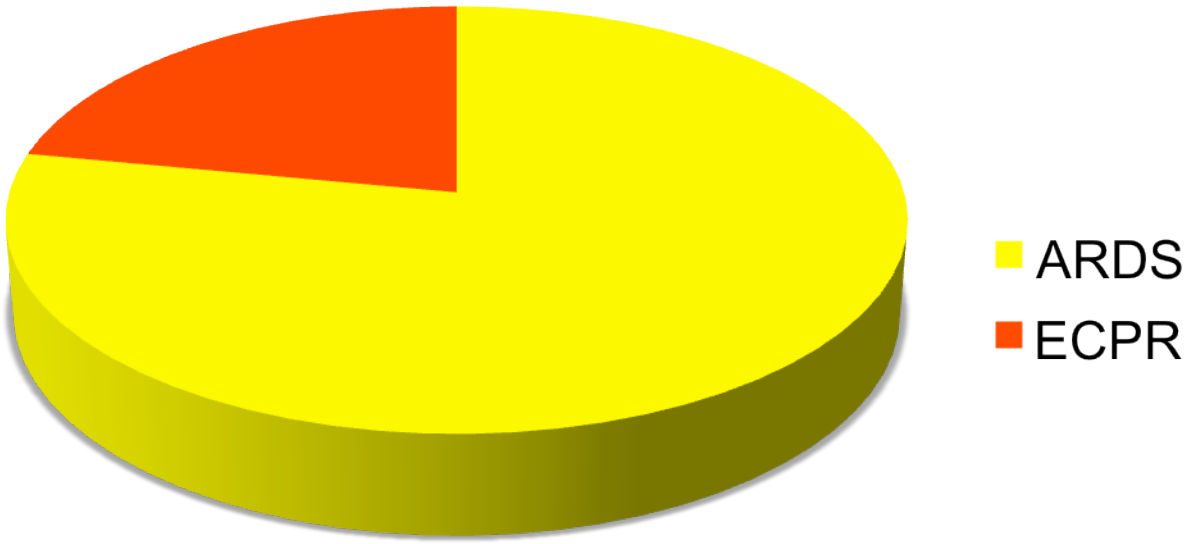

78% ARDS, 22% ECPR

One Year Survival

Survival All ECMO-Trauma (44%)

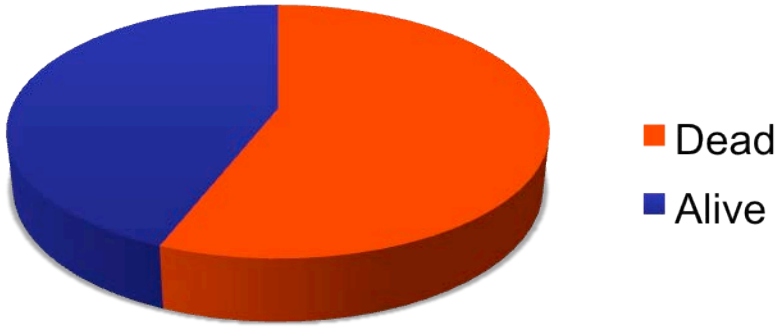

Survival ARDS (56%)

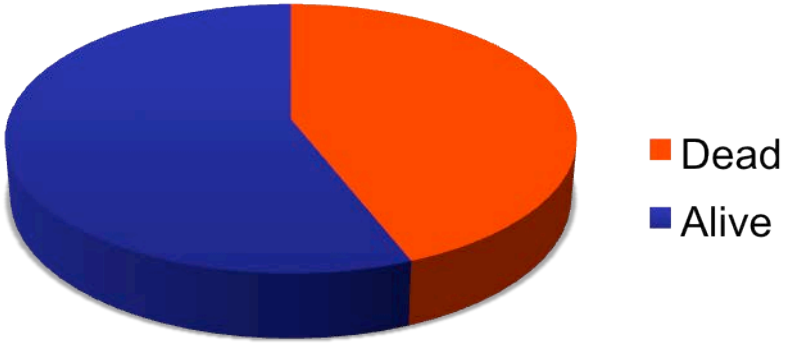

Survival ECPR Trauma(27%)

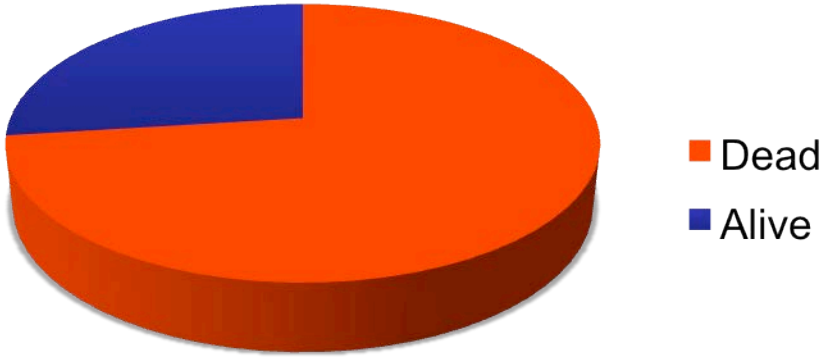

Non-Published data

Case 1: Mimmi 12 yo
(Hypovolaemic shock)

- ✓ Dog-pedestrian-truck
- ✓ HR 180, BP 60/40
- ✓ Temp. 32°C, pH 6.8
- ✓ Bil. pulmonary hemorrhage
- ✓ Liver injury grade V
- ✓ Unstable pelvic fracture
- ✓ Liverbleeding continues the whole night…….
- ✓ 50 L PRBC,FFP,TRC

- ✓ Transfusion Ass. Lung Injury

What to Do?

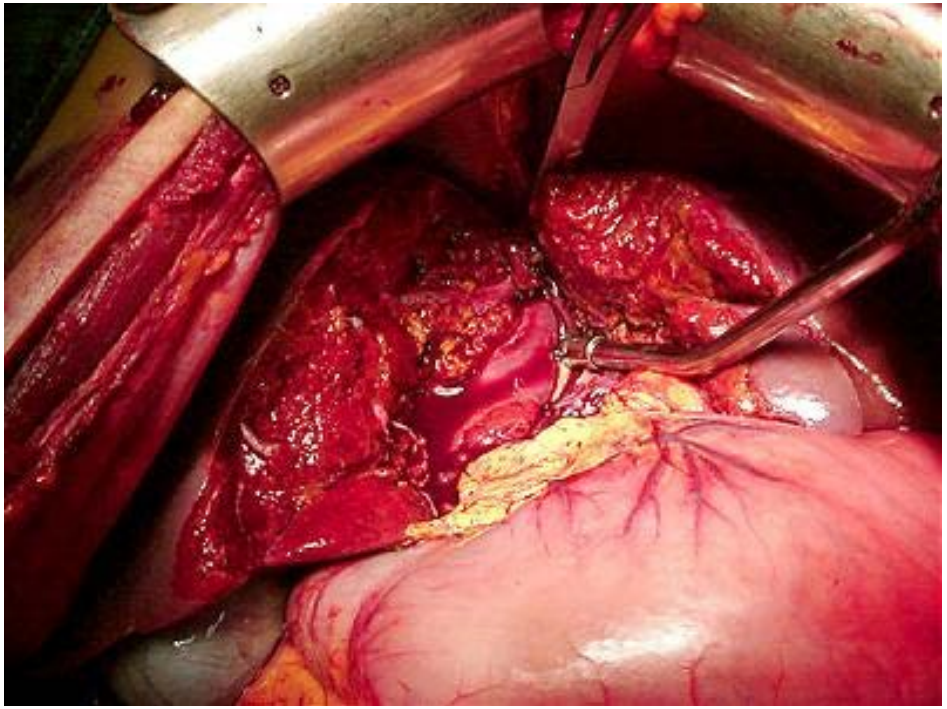

Case 1: Mimmi 12 yo

- ✓ VA ECMO (After 8 h)
- ✓ Liver bleeding ceased !?
- ✓ Packed abdomen
- ✓ Re-Lap, ECMO Weaning 52 h
- ✓ Survived wo handicap

What happened with the liver?

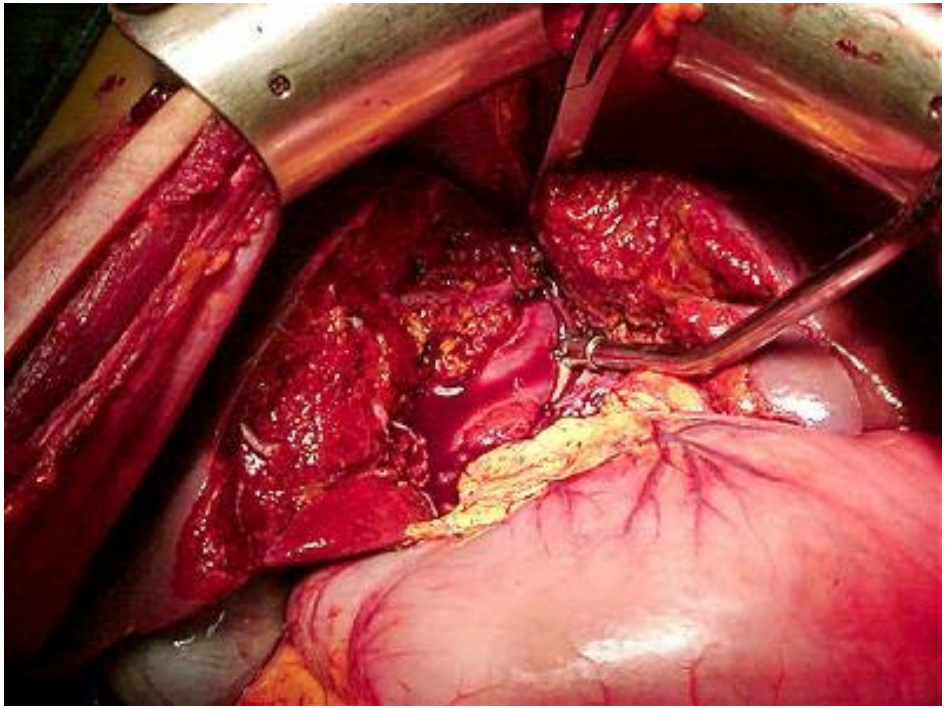

Increased right ventricular load

Pulmonary Resistence ↑

Central Venous pressure ↑

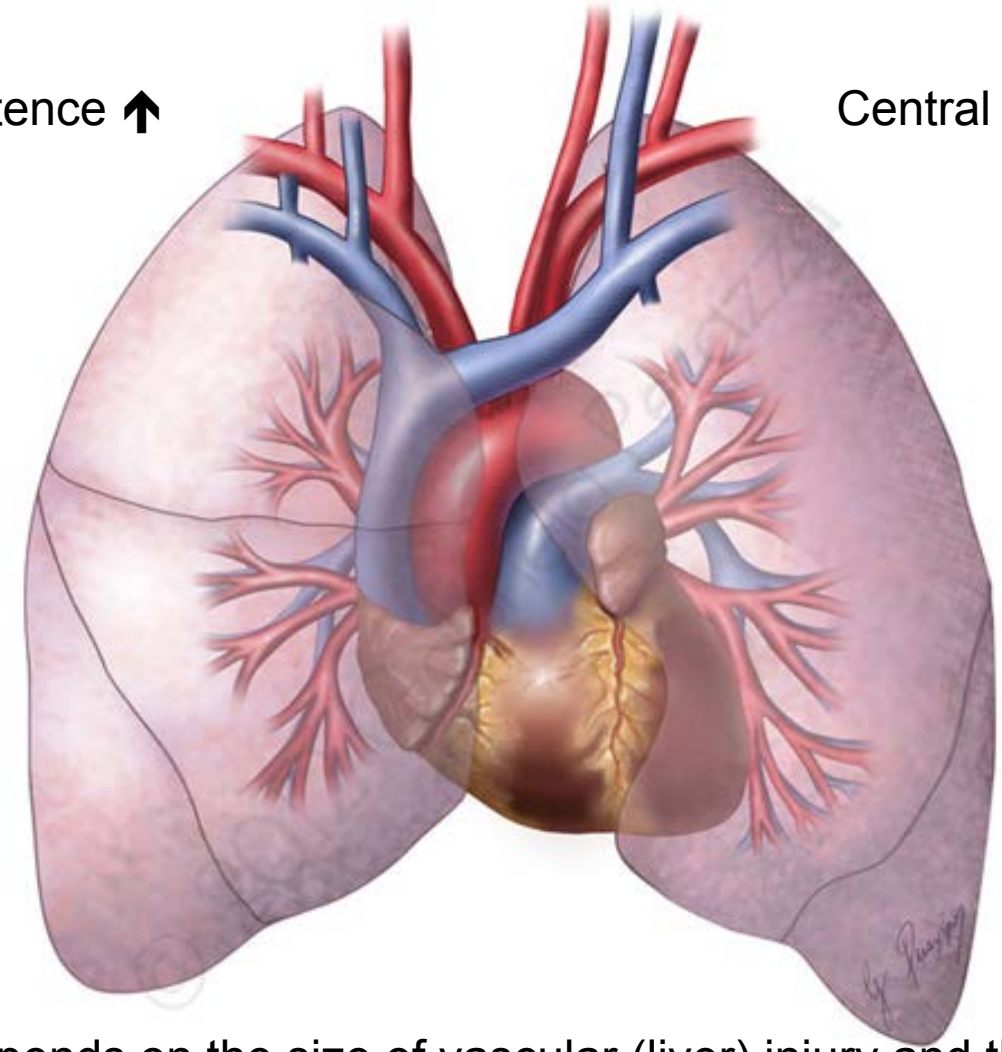

Venous bleeding depends on the size of vascular (liver) injury and the venous pressure

VA ECMO Reduced the Central Venous pressure

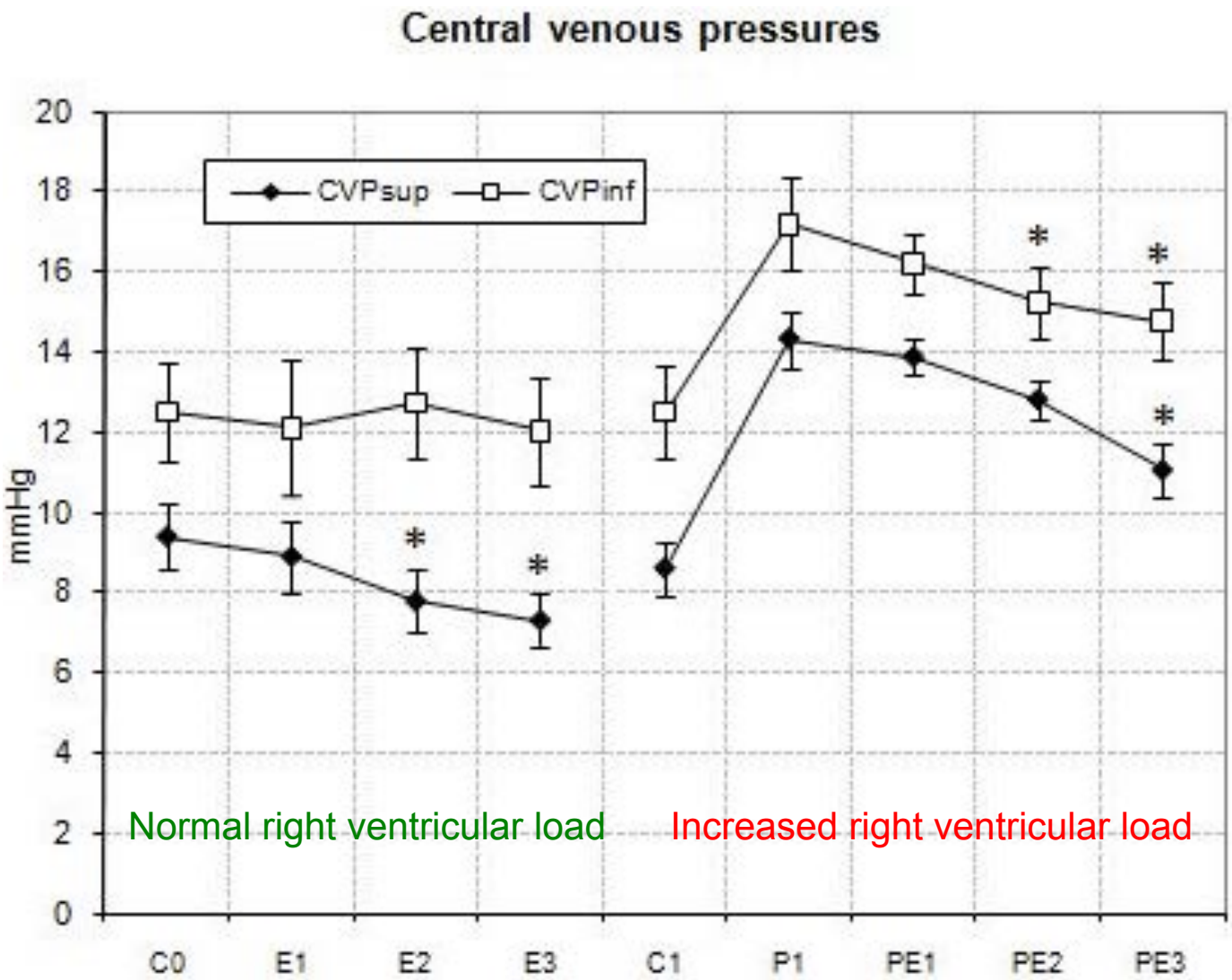

*) p<0.05, Dunett's post-hoc test

Larsson *et al.*, Perfusion 2010

ECMO improves coagulopathy

- 10 Rabbits bilat femurfractures and 45% bloodloss
- Near lethal shock 90 min.
- Hypothermia <32° C
- pH<7.0
- 5 Controll rabbits DCR, Retransfusion of warm blood
- 5 ECMO rabbits As above and VA ECMO
- <u>After 60 min ECMO:</u>

Temp. ↑ (*p=0.01)*

MAP↑ (*p=0.01*)

Acidosis↓(*p<0.01)*Lactate↓(*p<0.01)*

Rotem CFT↓(*p<0.01)*

In Vivo bleeding↓(*p<0.01)*

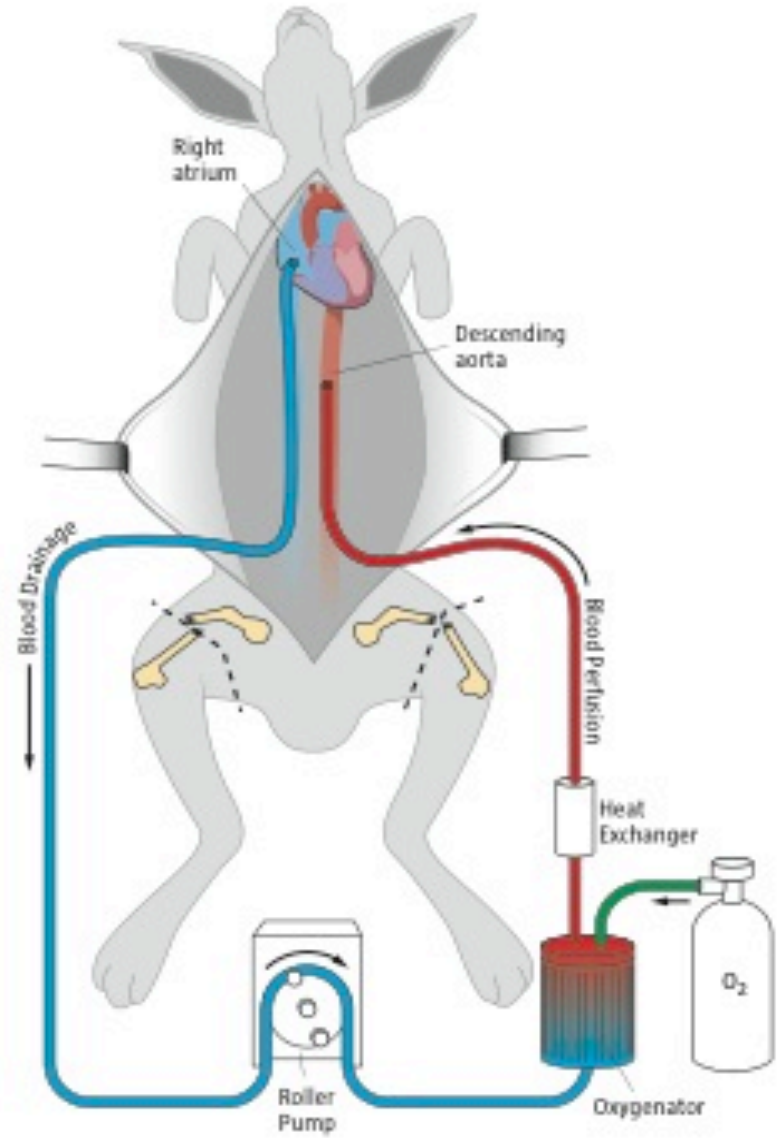

Larsson et al Eur J Trauma Emerg Surg. 2016

Case 2: Anna 18 yo
(Cardic Arrest)

- ✓ Suicide attempt-Ethanol-Found between trainwaggons
- ✓ Bilat hemothorax-Drain x 2
- ✓ Unstable Pelvic fracture
- ✓ Abd. Compartment-laparotomy
- ✓ Massive lung-bleeding-hypoxia
- ✓ Cardiac Arrest

What to Do ?

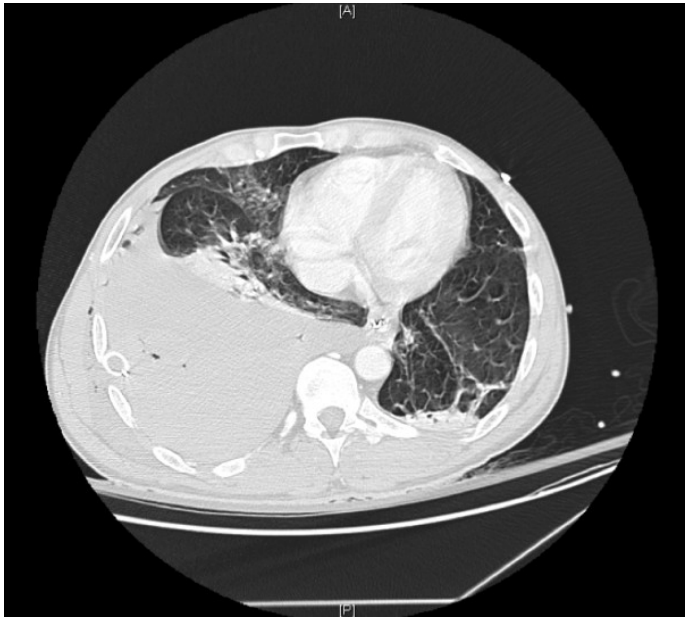

Case 2: Anna 18 yo

(Cardic Arrest)

- ✓ Cannulation left groin (21F-V x 2 17F-A, 8F-dist)
- ✓ VA-ECMO wo Heparin
- ✓ 198 U PRBC+FFP, 15 U Tromb (54L)
- ✓ Heart stun
- ✓ Thoracotomy dx-iatrogen lungbleeding
- ✓ Conv to VV-ECMO (2days)
- ✓ Off ECMO (3 days) 96h
- ✓ Survived wo neurological deficit

Advanced Extracorporeal therapy in trauma

- ✓ Review December 2016
- ✓ ECLS/ECMO use increases in trauma
- ✓ Survival 65-79%
- ✓ Early implementation may increase survival
- ✓ Heparin-free treatment (1-5 days)
- ✓ Percutaneous cannulation recommended
- ✓ Prospective studies are needed

Zonies. Curr Opin Crit Care 22(6) 2016

Success factors

- ✓ Dedicated ECMO team including trained surgeon available in short time
- ✓ Early consultation-decision-implementation
- ✓ Multiple cannulaes for groin cannulation
- ✓ High-speed fluid line, enabling fast high-volume transfusion
- ✓ Short By pass time

Arlt *et al*. Extracorporeal membrane oxygenation in severe trauma patients with bleeding shock., Resuscitation 2010

ECMO-Trauma Summarry

- ✓ ECMO is NOT Rocket Science
- ✓ Easy and fast to cannulate
- ✓ Supports heart-lung functions
- ✓ Reduces central venous pressure
- ✓ Increases MAP
- ✓ Rewarms efficiently (<60 min)
- ✓ Fights lactate and acidosis
- ✓ May improve coagulation
- ✓ Extended OR-ICU
- ✓ No Heparin is needed in the first 24-48 h.

What if all traumavictims got a CV-Line and Arterial line in the Groin….?

ECMO in trauma

Soon on a theater near You!

magnus.j.larsson@sll.se

Coagulopathy in trauma-The Lethal Triad

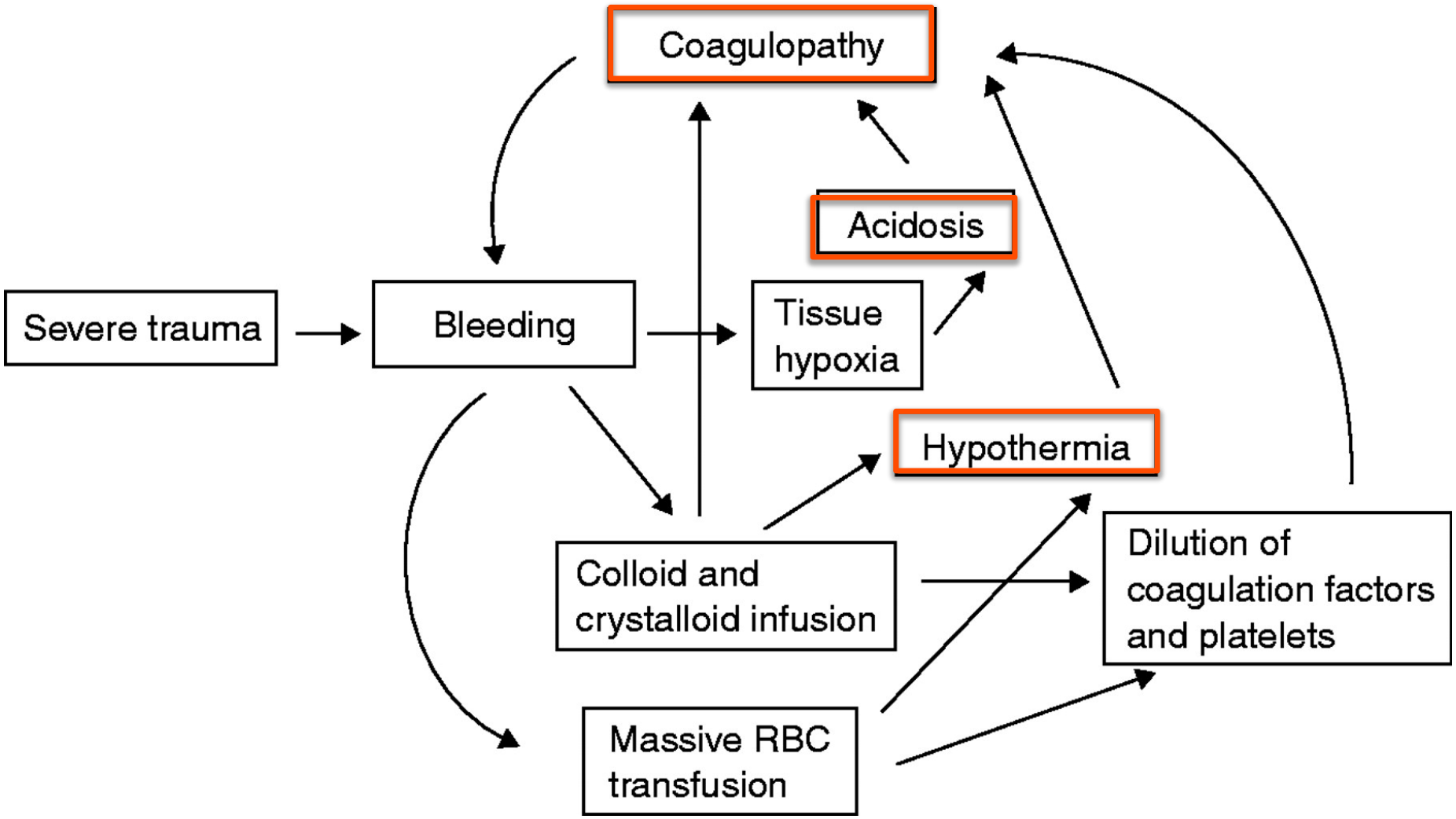

Spahn D R , and Rossaint R Br. J. Anaesth. 2005;95:130-139

BJA British Journal of Anaesthesia

Speculations on Indications/contraindications ECMO-Trauma

Indications

- ✓ ARDS
- ✓ Hypovolaem chock not respondning to conventional treatment?
- ✓ Coagulopathy?

  (pH<7 T.<34°C?)
- ✓ By Pass of bleeding organs Liver? Lung? Heart?

Contraindications

- ✓ Non-reversible life-threatening disease (cancer)
- ✓ Severe Brain-injury

Decision to withdraw the treatment is as important as the initiation

ECMO center Karolinska

- ECMO – Intensivvårds avd m 6 platser
- Cirka 100 patienter per år
- 60% neonatala / pediatriska
- > 1200 ECMO patienter
- 840 transporter
- Få Hjärt-fall, ffa mer komplexa längre behandlingar Pneumoni, Sepsis, PHT, CDH, MAS, etc.
- ELSO centre of excellence de senaste 8 åren.
- 1 Läkare /2-3 patienter, 1 Sjuksköterska /1-2 patienter och 1 Undersköterska/2-3 patienter